PET-TC e metastasi cerebrali da neoplasia mammaria

Dott. Matteo Salgarello
Medicina Nucleare, Terapia Radiometabolica
Ospedale Sacrocuore Don Calabria

PET-TC FDG non risulta sufficentemente accurata per la stadiazione e ristadiazione di secondarietà cerebrali da neoplasia primitiva della mammella

In Medicina Nucleare, il concetto fondamentale consiste nell'introdurre in un processo fisiopatologico un metabolita riconoscibile, seguirne il destino e trarne informazioni relative al comportamento dell'intero sistema. In questo, la PET non differisce concettualmente dalla M.N. tradizionale: ciò che determina il salto di qualità sono le peculiari caratteristiche dell'imaging a positroni e la possibilità di disporre di molecole biologiche le più svariate possibili.

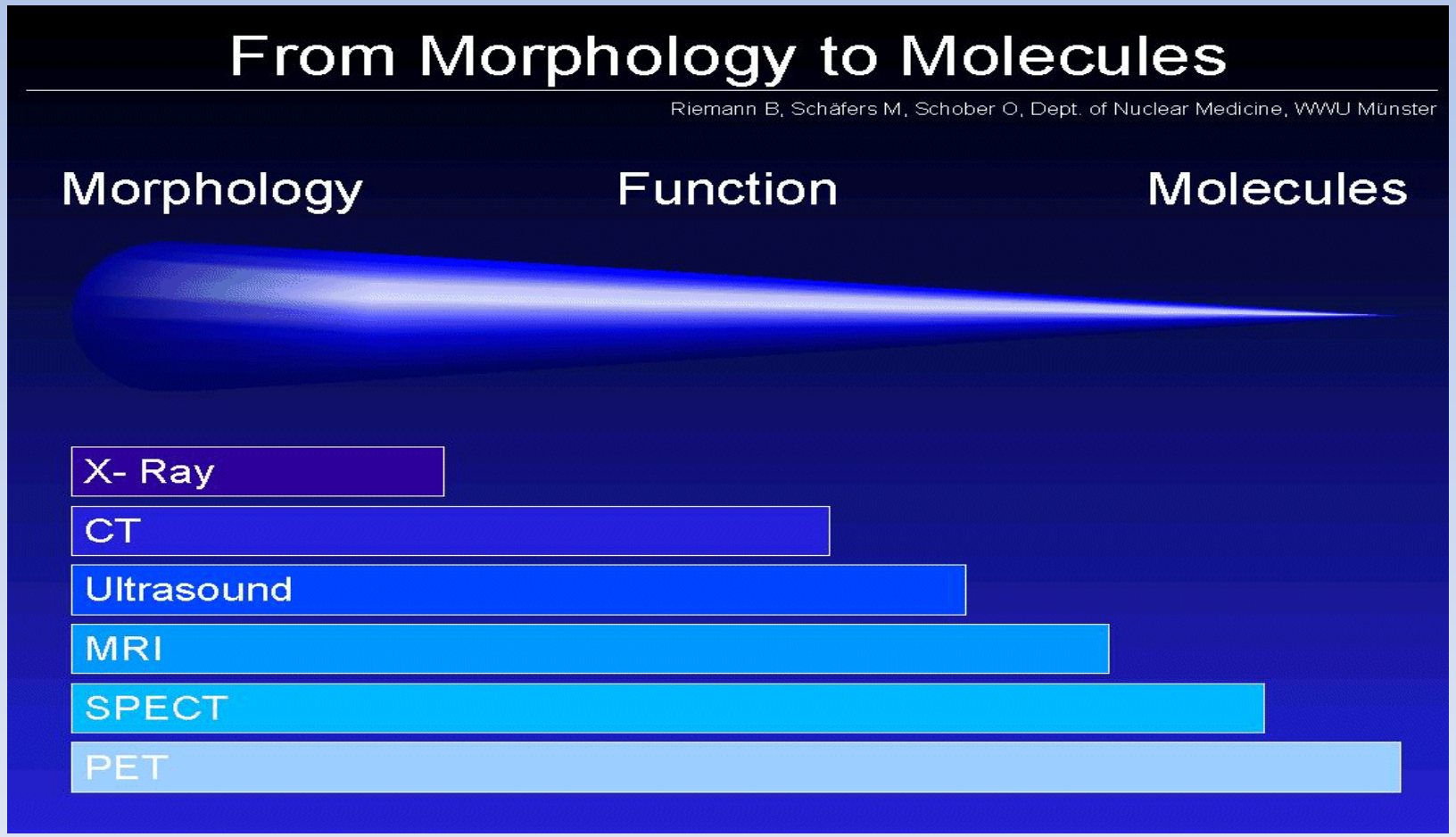

Selected targets and corresponding nuclear imaging probes already established for nuclear molecular imaging in the clinic or currently under assessment in clinical studies

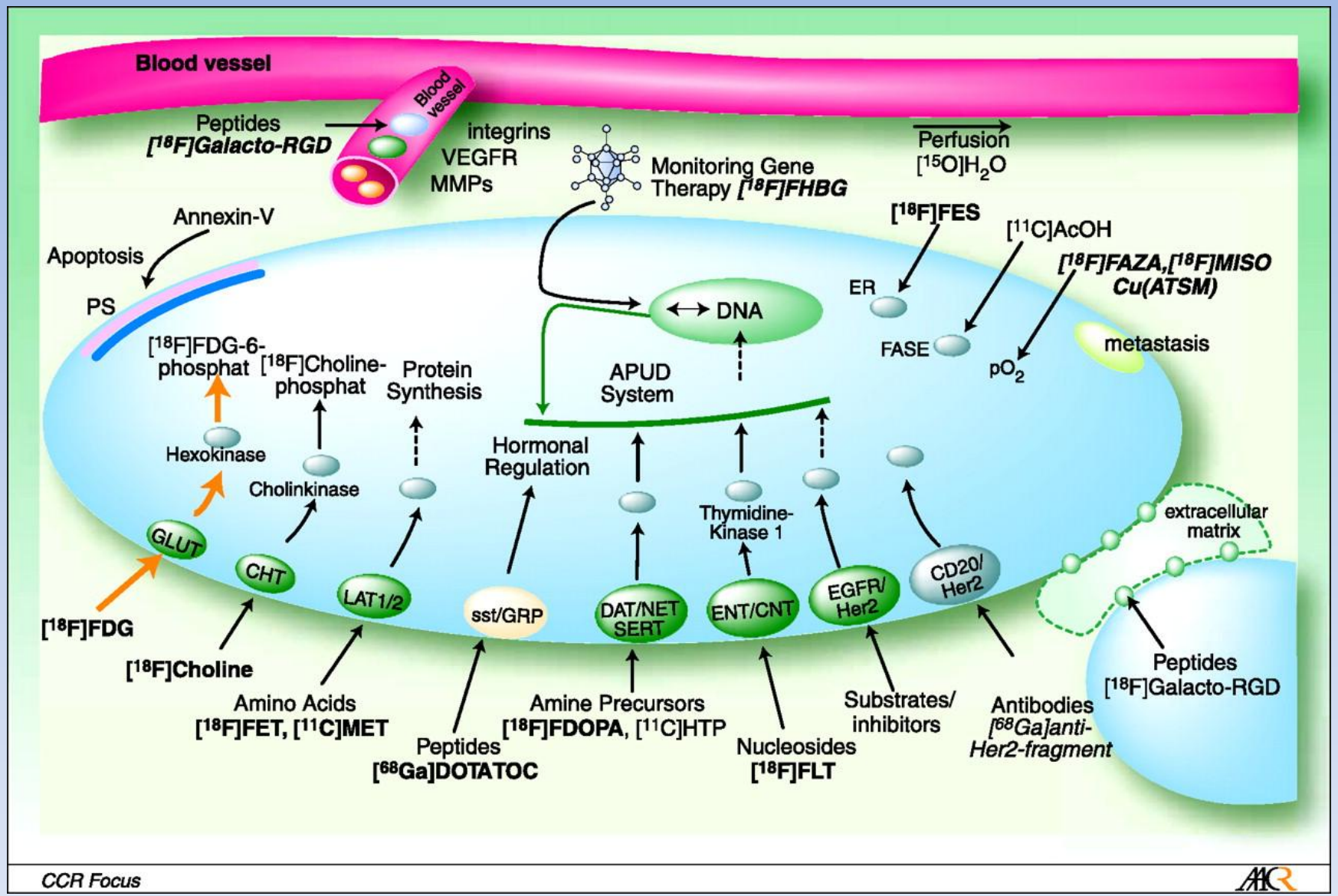

Wester H Clin Cancer Res 2007;13:3470-3481

AACR Clinical Cancer Research

Selected targets and corresponding nuclear imaging probes already established for nuclear molecular imaging in the clinic or currently under assessment in clinical studies

E' veramente l'unica informazione oncologicamente rilevante?

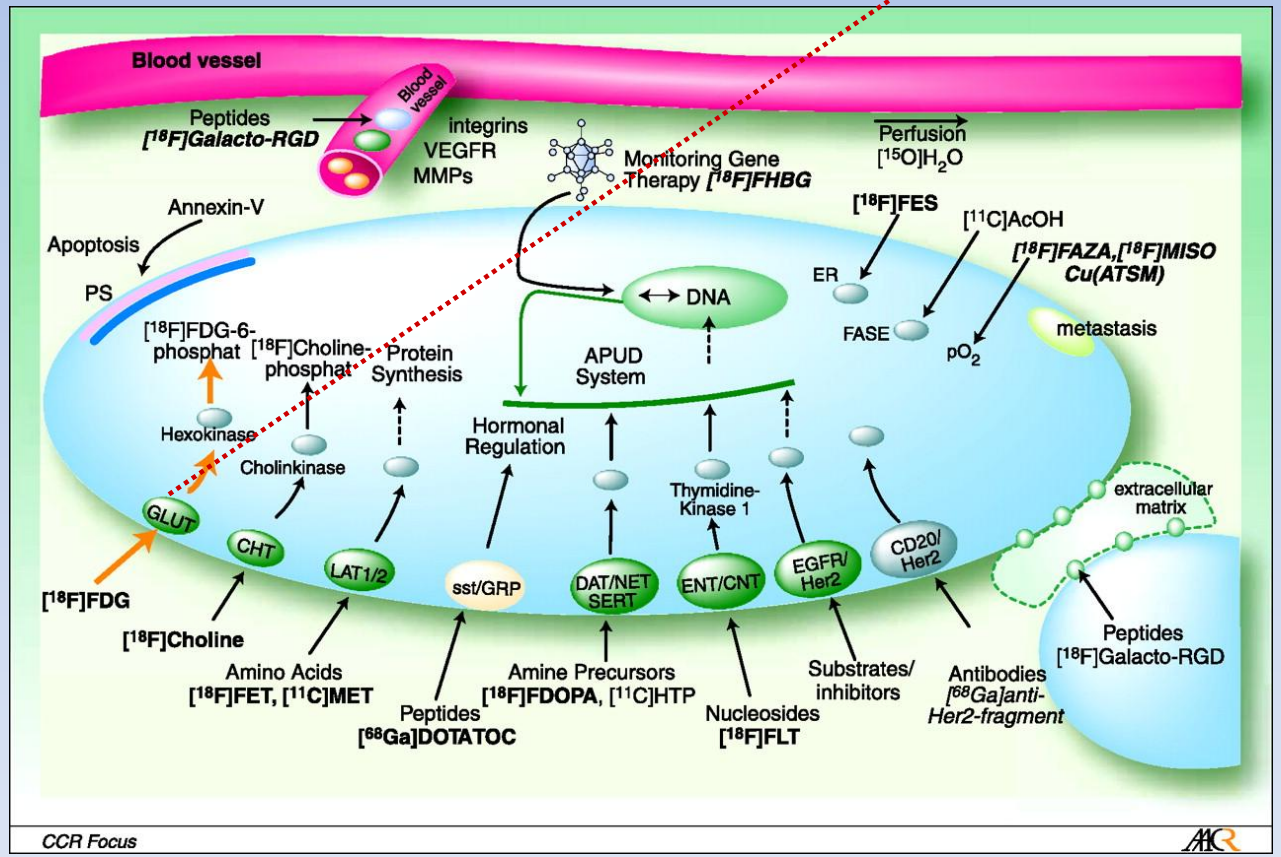

Wester H Clin Cancer Res 2007;13:3470-3481

Clinical Cancer Research

L' FDG iniettato al paziente agisce come tracciante della glicolisi e si accumula maggiormente in sedi ove questa via metabolica è attivata in misura abnorme rispetto al consueto metabolismo aerobico, cosa che avviene in varie condizioni patologiche, come ad esempio nel contesto di tumori primitivi e di loro metastasi.

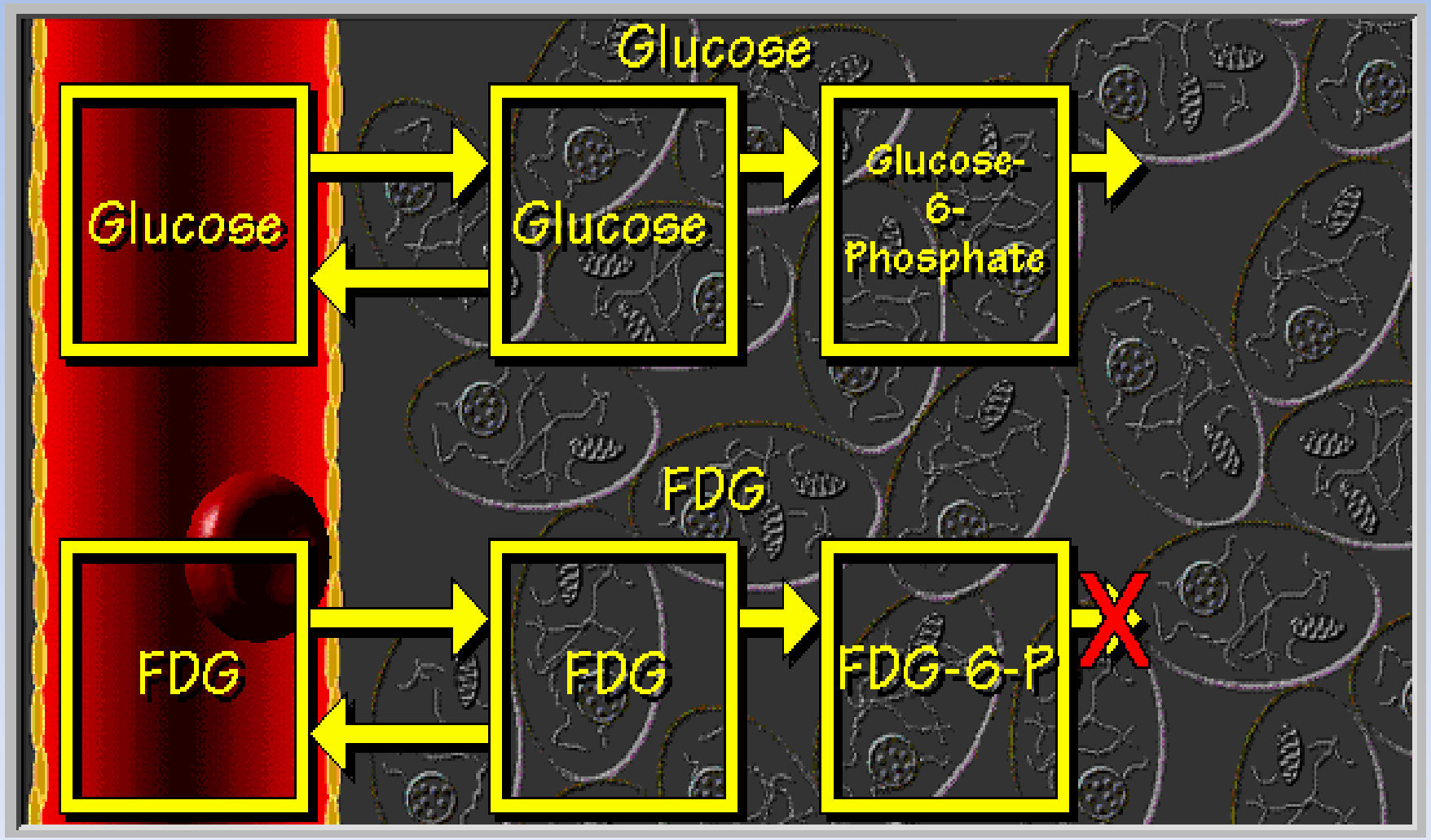

Normale biodistribuzione

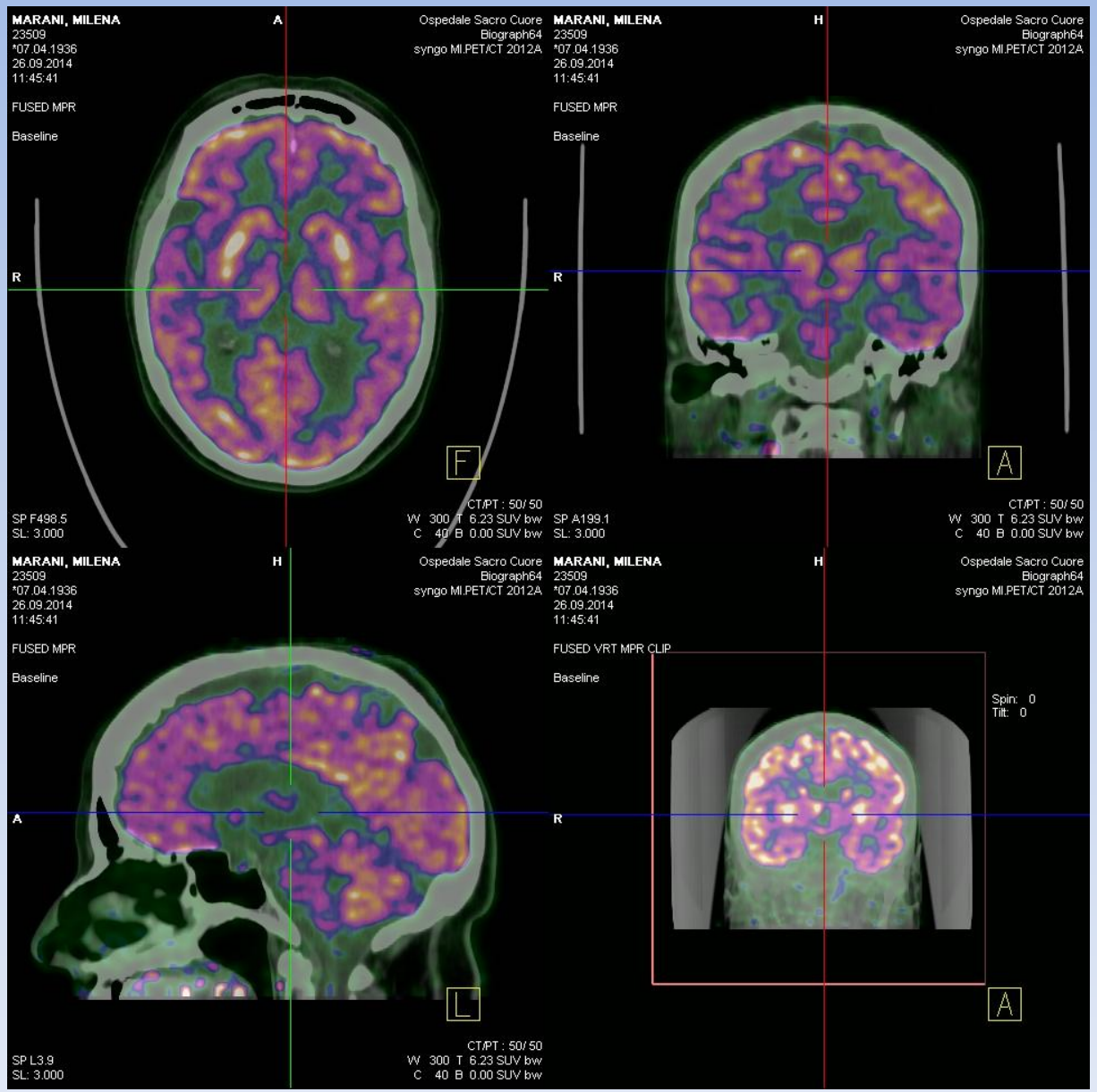

PET-CT cerebrale
metabolismo FDG normale

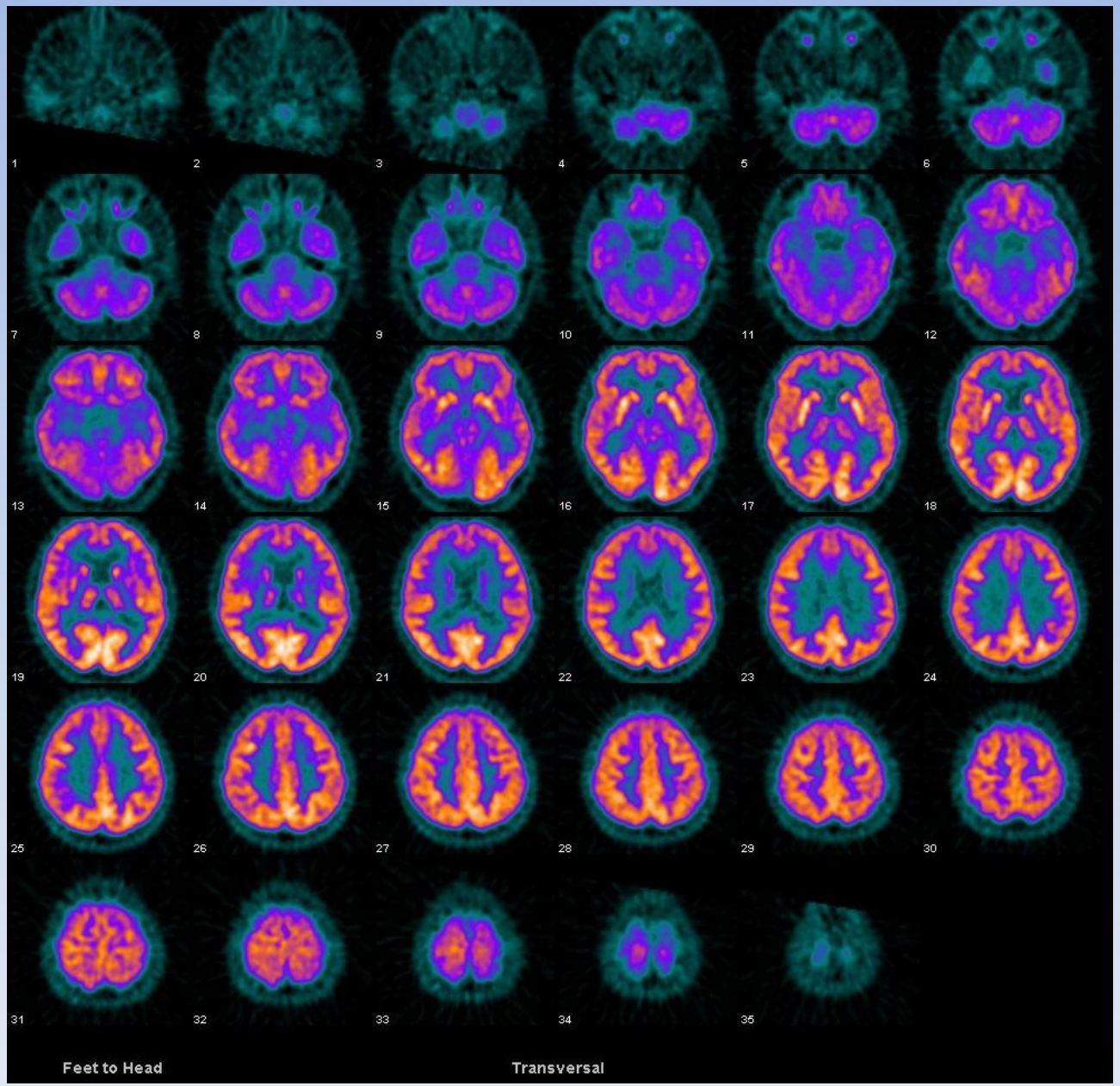

Dual phase FDG-PET imaging of brain metastases provides superior assessment of recurrence versus post-treatment necrosis.

J Neurooncol. 2011 May;103(1):137-46

PET-CT cerebrale ^{11}C-METIONINA metabolismo degli aminoacidi

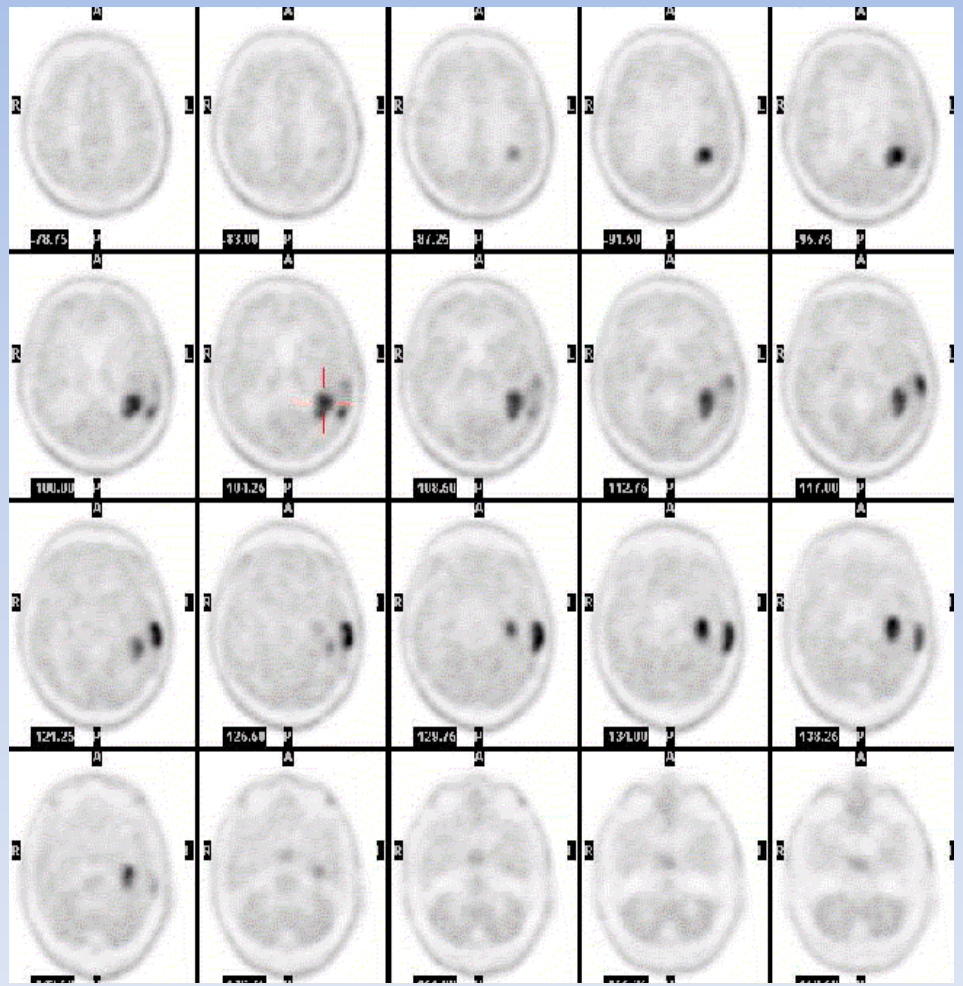

PET-CT cerebrale ^{11}C-COLINA metabolismo dei fosfolipidi

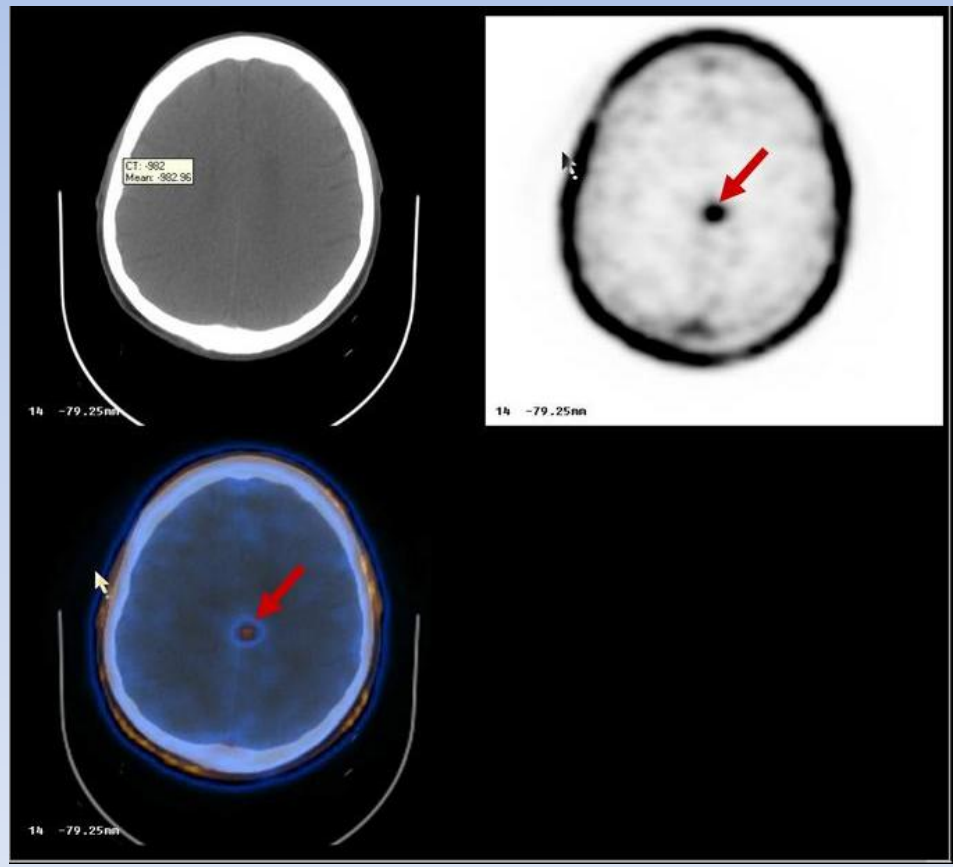

PET/CT changed diagnosis in 21% of breast cancer patients under 40

Journal of Nuclear Medicine sept 2014. Memorial Sloan Kettering

Patients less than 40 years of age originally diagnosed with one of the first three stages of breast cancer underwent a change in clinical staging as a result of PET/CT scanning, according to a study announced Oct. 1 by the Society of Nuclear Medicine and Molecular Imaging (SNMMI).

General breast-cancer imaging guidelines recommend FDG PET imaging only for patients with stage III breast cancer. However, research conducted at Memorial Sloan Kettering by Christopher C. Riedl, MD, and colleagues revealed that PET/CT imaging in earlier stages of disease can set a more accurate and effective path of treatment, especially for younger patients who may have aggressive forms of cancer. Results of the retrospective analysis were first published Sept. 11 in the *Journal of Nuclear Medicine* .

The study involved 134 patients diagnosed with stage I-III breast cancer excluding women with prior malignancy or distant metastases. Results of the analysis showed clear up-staging to stage III or IV breast cancer in 28 patients, or 21 percent. Of the 134 patients reviewed, 20 had distant metastases and 15 had extra-axillary regional nodes, or 15 percent and 20 percent, respectively. A total of seven women were found to have both, or 5 percent. Further delineations were made for stages IIA and IIB and IIIA and IIIB. All stage IV up-staging was confirmed with histology.

"Overall F-18 FDG PET/CT revealed stage IV disease in 10 percent of breast cancer patients younger than 40 years with clinical stage I and II breast cancers," concluded Riedl et al in the published study. "In particular, 17 percent of women younger than 40 years with stage IIB disease were found to have distant metastases. Although current National Comprehensive Cancer Network breast cancer guidelines recommend against systemic staging with F-18 FDG PET/CT in women with stage II disease and recommend that use of the modality be considered optional for the work-up of stage III breast cancer, our data suggest that women younger than 40 years might benefit from PET/CT staging even at stage IIB."

Researchers still need to conduct a larger prospective study that reduces any potential selection bias to validate these findings, but this preliminary research opens the door to future PET studies that look at factors beyond age to clarify which patient populations benefit most from PET imaging.

"Future NCCN guidelines for initial staging of breast cancer patients may need to consider other factors in addition to clinical stage," said Gary Ulaner, MD, PhD, assistant professor at Memorial Sloan Kettering in the official SNMMI statement. "This study provides further evidence that molecular imaging and nuclear medicine can help us make better cancer staging and treatment decisions

Prognostic value of quantitative fluorodeoxyglucose measurements in newly diagnosed metastatic breast cancer.

Cancer Med. 2013 Oct;2(5):725-33. Memorial Sloan-Kettering Cancer Center, New York, New York

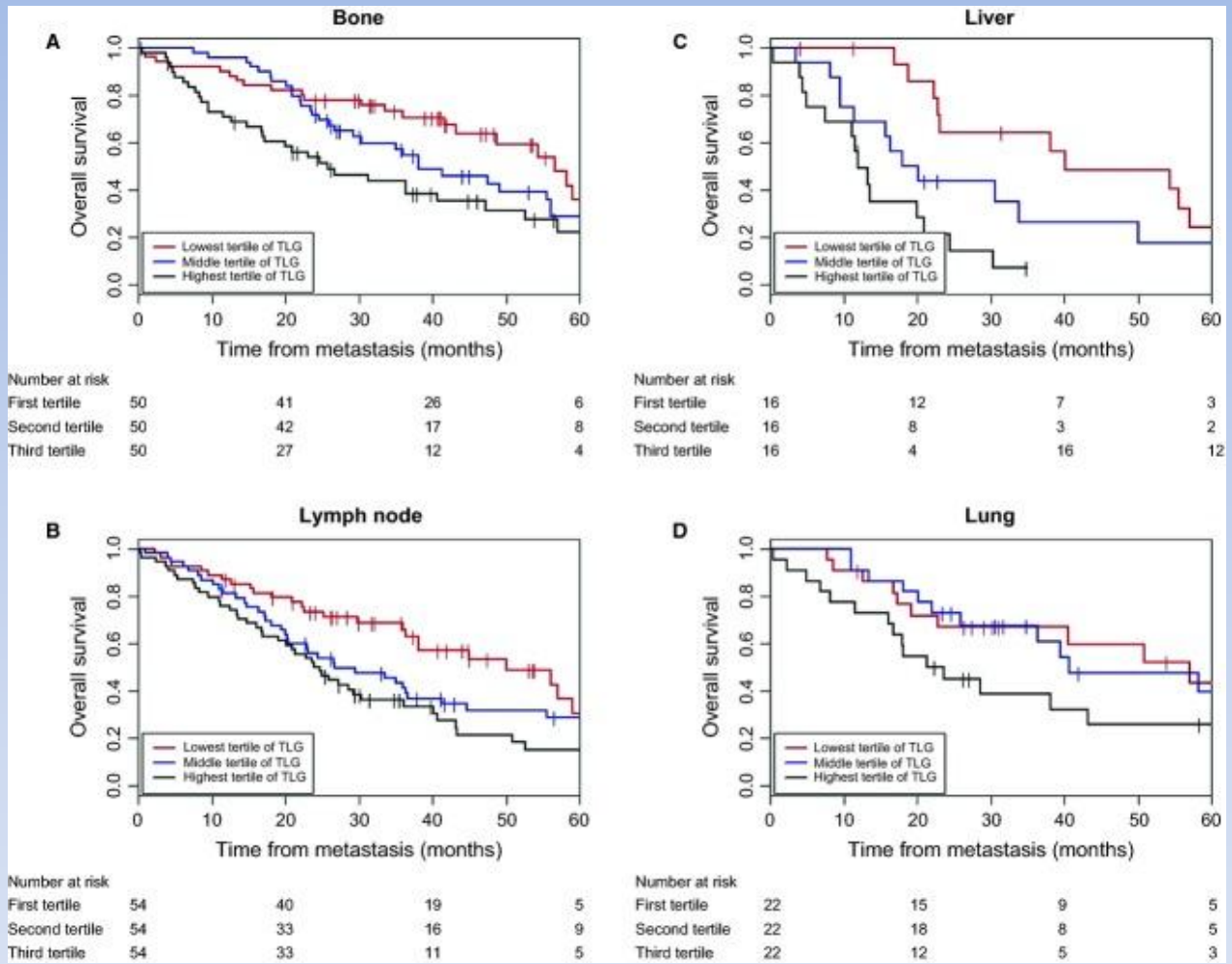

Kaplan–Meier curves of overall survival (OS) according to total lesion glycolysis tertiles (TLG) in (A) bone, (B) lymph node, (C) liver, and (D) lung. Time point zero is defined as the date of diagnosis of metastatic disease. Number of patients at risk for death at selected time points is displayed below each graph.

Role of maximum standardized uptake value in fluorodeoxyglucose positron emission tomography/computed tomography predicts malignancy grade and prognosis of operable breast cancer: a multi-institute study.

Breast Cancer Res Treat. 2013 Sep;141(2):269-75..

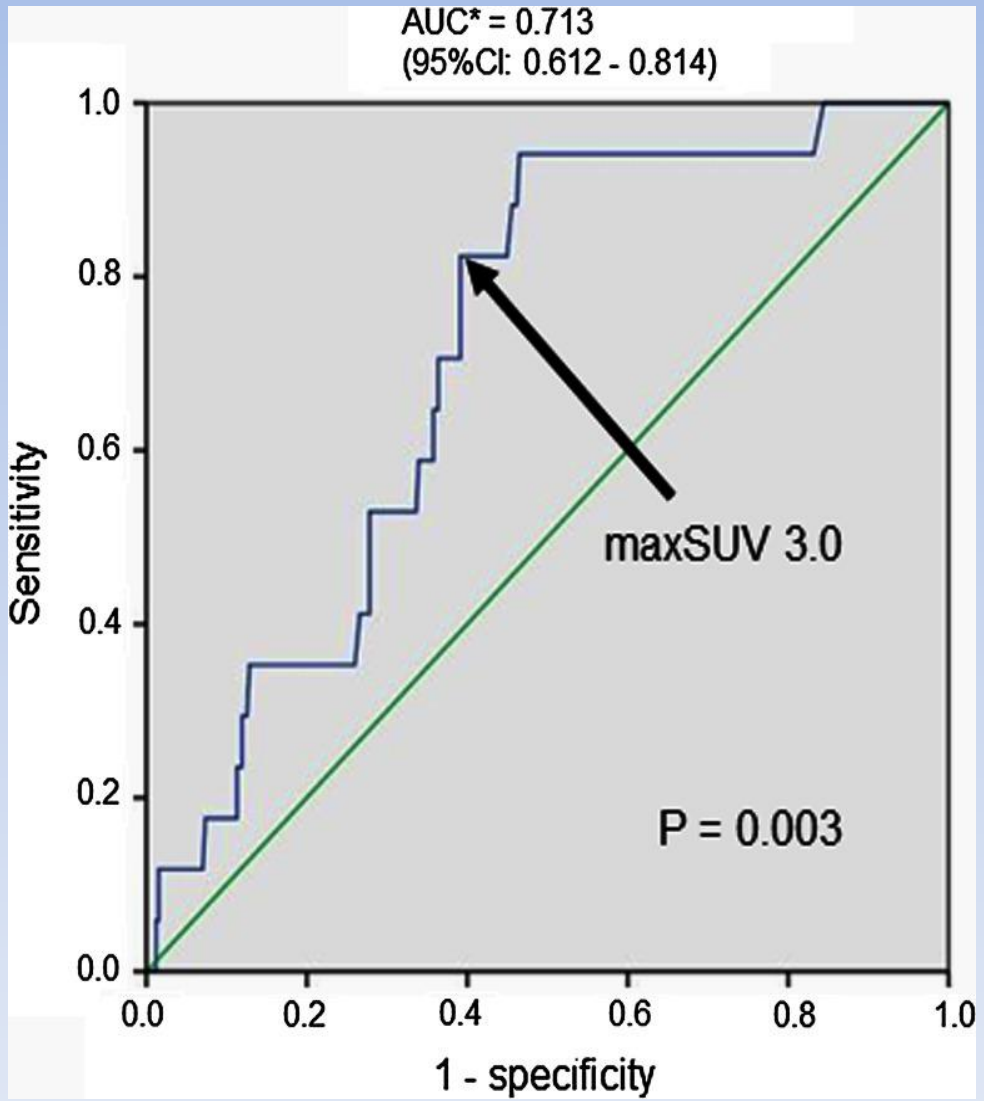

Role of maximum standardized uptake value in fluorodeoxyglucose positron emission tomography/computed tomography predicts malignancy grade and prognosis of operable breast cancer: a multi-institute study.

Breast Cancer Res Treat. 2013 Sep;141(2):269-75.

Department of Surgical Oncology, Research Institute for Radiation Biology and Medicine, Hiroshima University

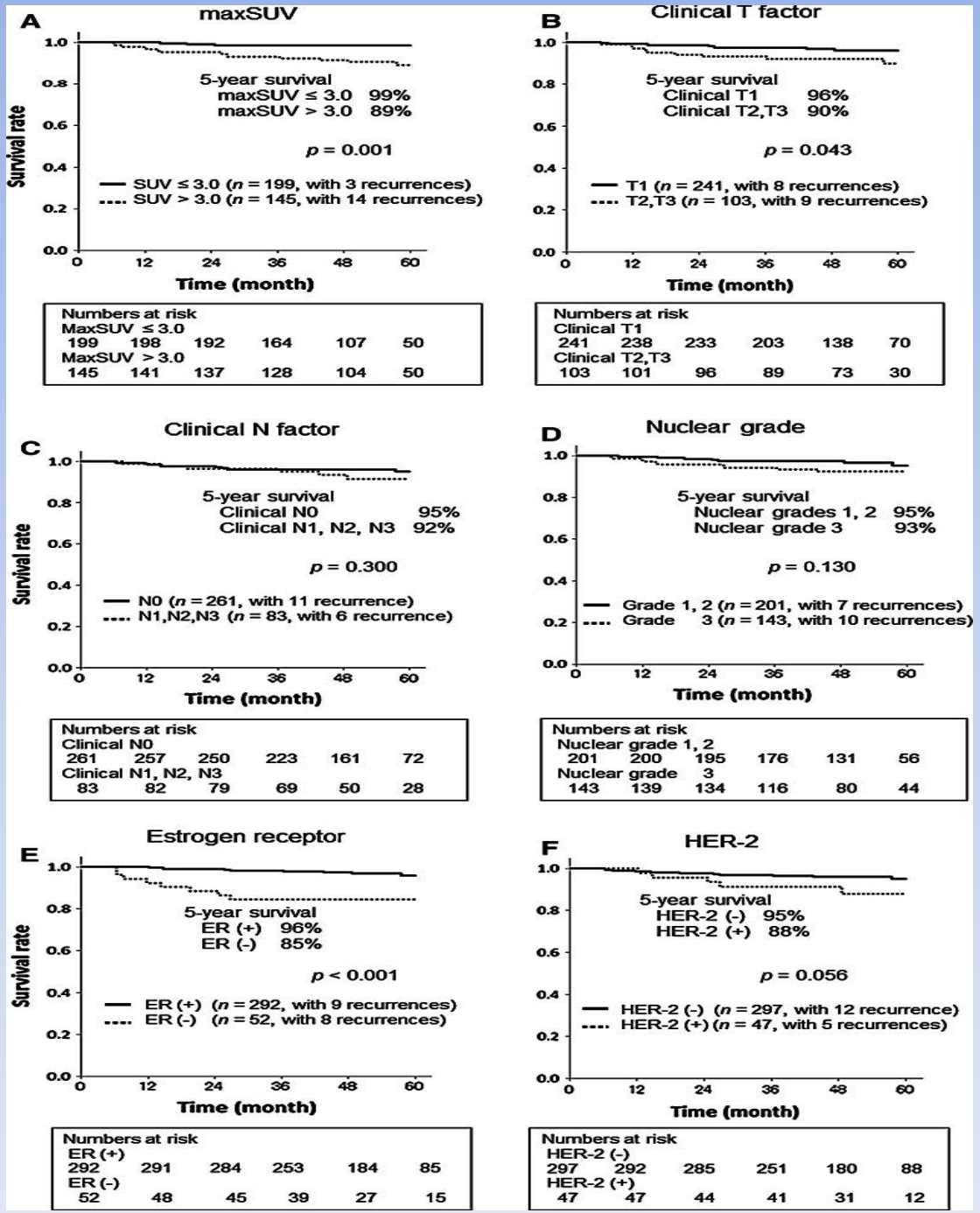

Recurrence-free survival (RFS) curves of patients according to predictive factors. 5-year RFS rates for patients with:

a maxSUV ≤ 3.0 and >3.0,

b clinical T-factor T1 and T2, 3,

c clinical N-factors N0 and N1, 2, 3,

d nuclear grades 1, 2, and 3

e ER (+) and ER (–)

f HER2 (–) and HER2 (+)

Treatment/functional imaging of Breast Cancer Brain Metastases

Approximately 10% to 15% of women with metastatic breast cancer will develop brain metastases.

Treatment options for these women remain limited, particularly at the time of central nervous system(CNS) relapse following completion of initial CNS-directed therapy.

Historically, prior studies have broadly examined systemic treatments for breast cancer brain metastases with mixed, but overall disappointing, results.

More recently, studies have increasingly selected patients based on breast cancer subtype and have examined novel, targeted agents that have preclinical suggestion of blood–brain barrier penetration.

Correlative science objectives, with both tissue-based and novel imaging endpoints, are more frequently incorporated into trials of this nature, with the goal of enhancing our understanding of possible predictors of response.

Local Therapies to Treat Breast Cancer Brain Metastases

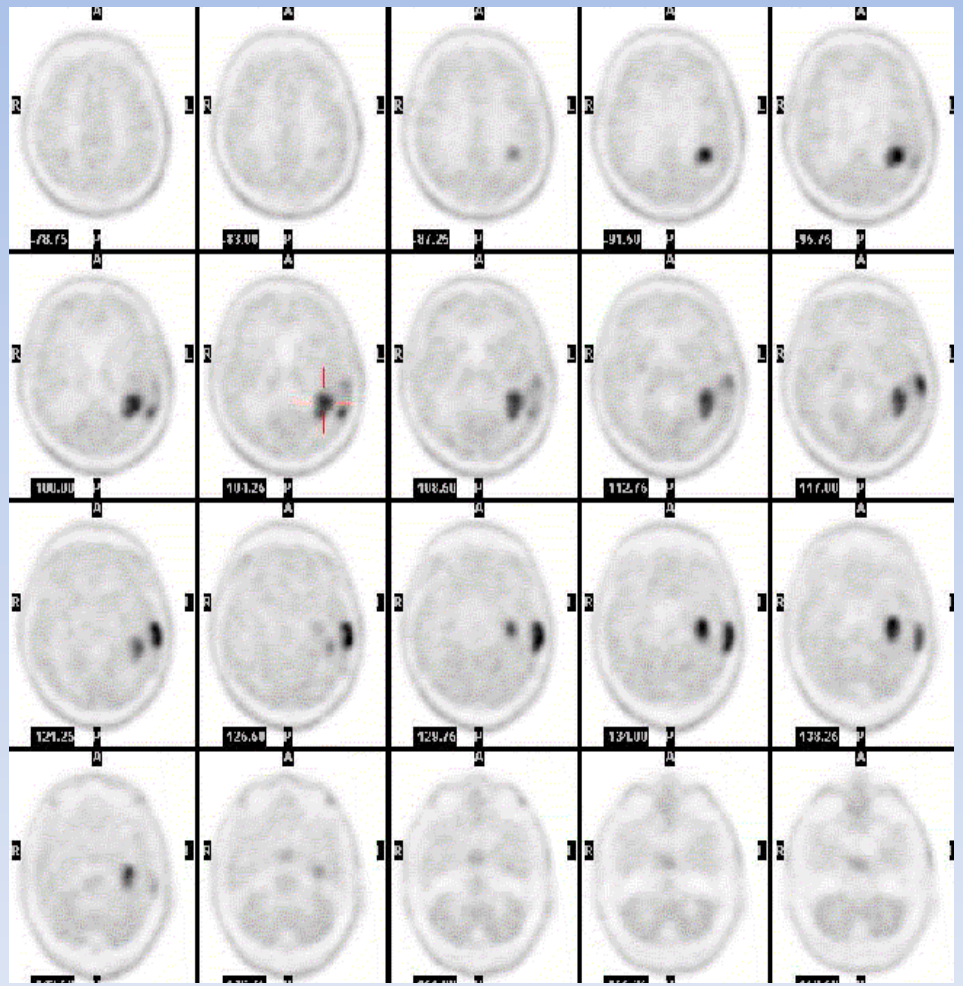

11C-Metionina Gold Standard

Chemotherapy for Treatment of Breast Cancer Brain Metastases

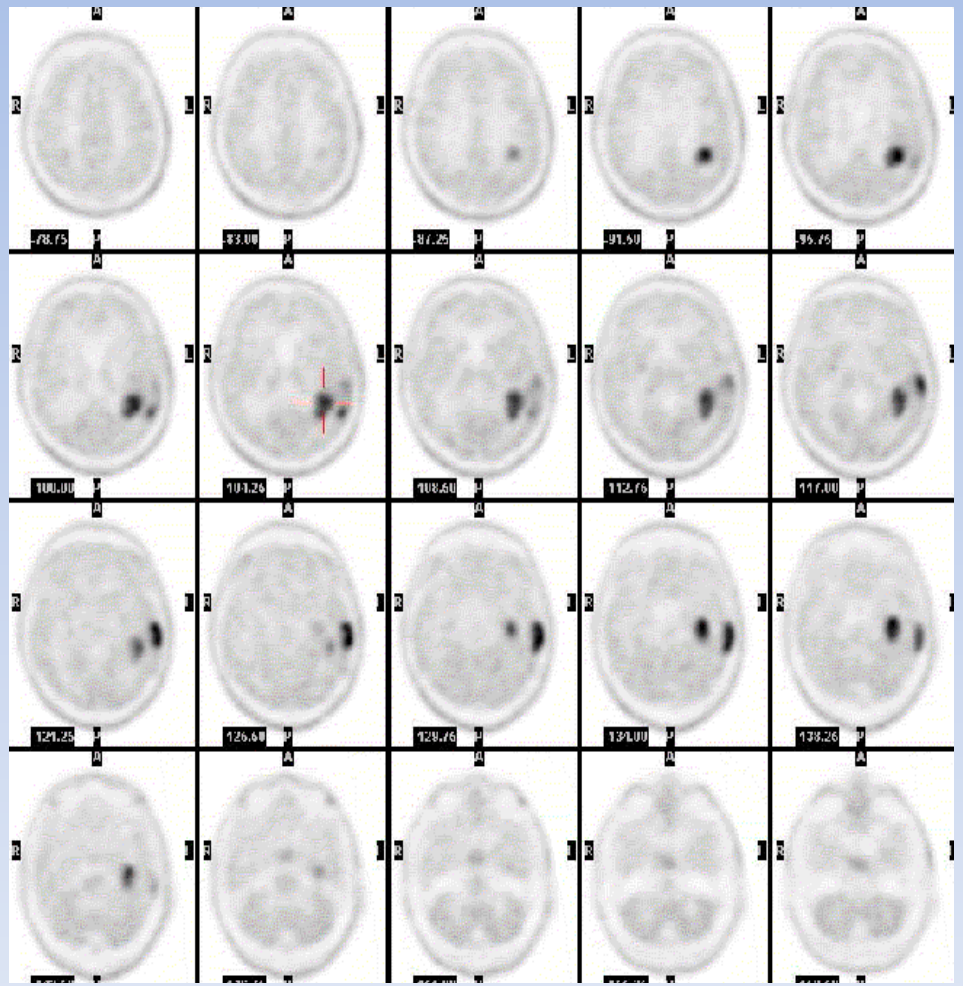

11C-Metionina Gold Standard

18F-Thyrosina (l'attività della tirosina chinasi)

18F-Timidina (attività della timidina chinasi)

HER2-Directed Therapy

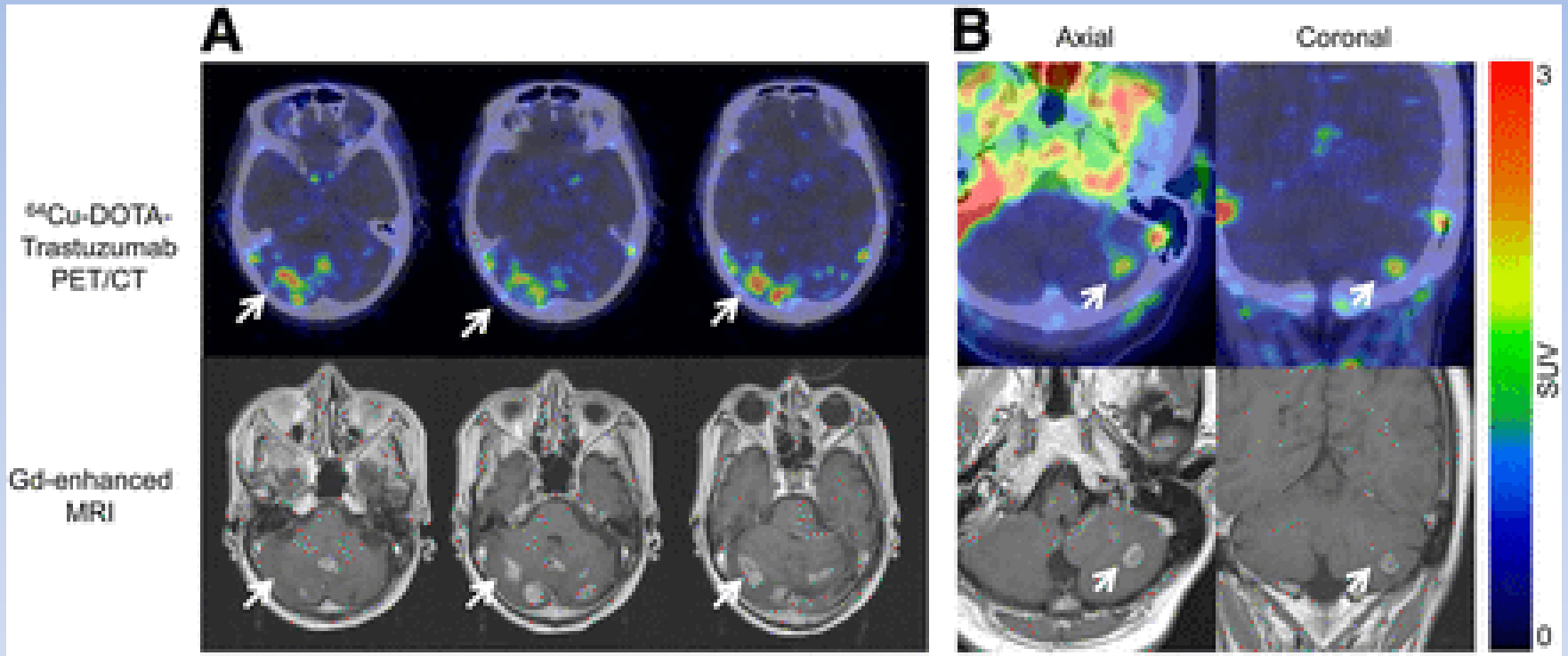

Disponibile ormai molti studi anche con 89Zr-Trastuzumab

^{64}Cu-DOTA-Trastuzumab PET Imaging in Patients with HER2-Positive Breast Cancer

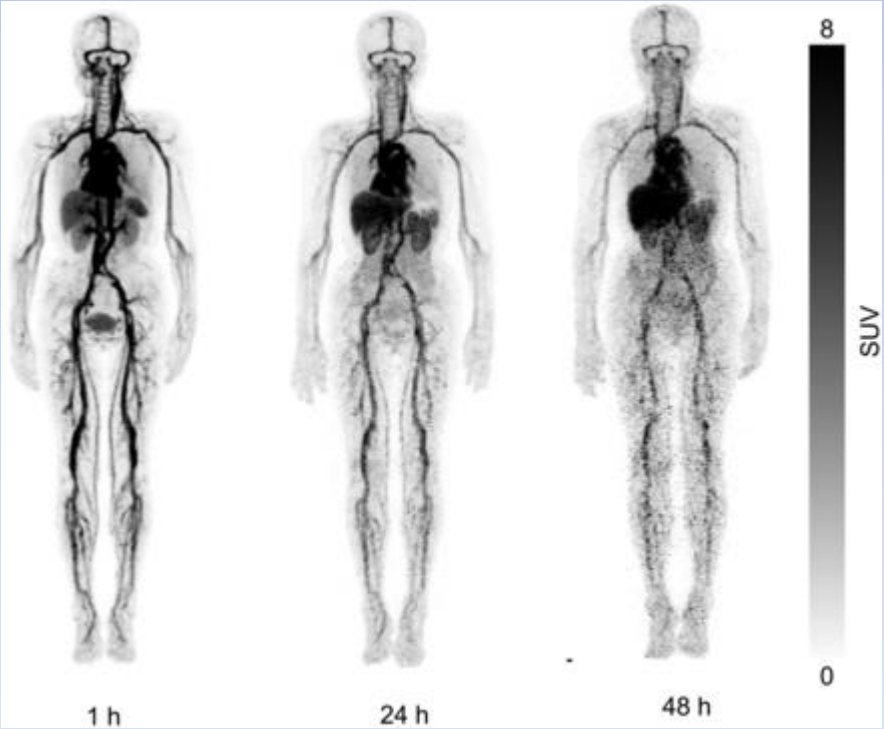

^{64}Cu-DOTA-Trastuzumab PET Imaging in Patients with HER2-Positive Breast Cancer

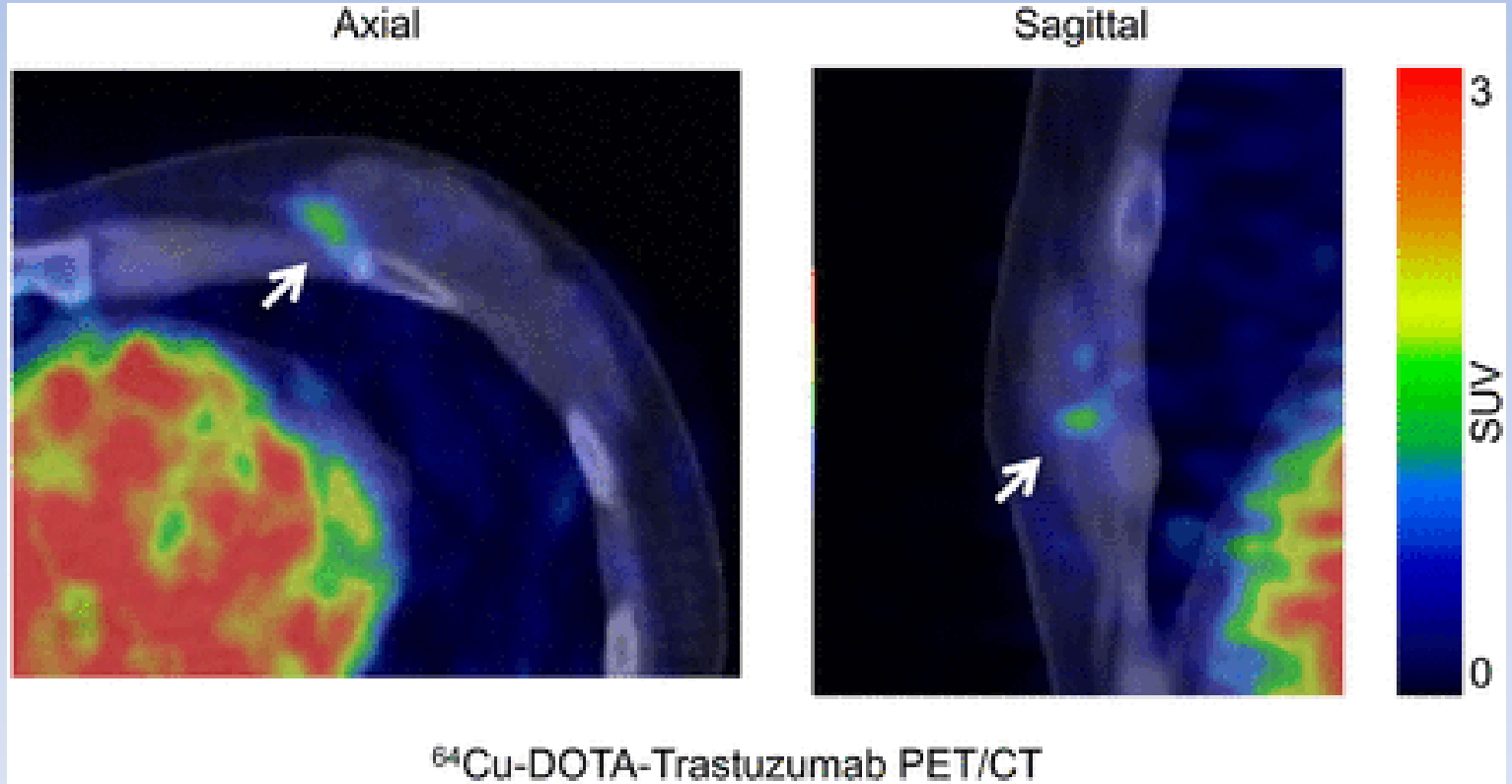

Antiangiogenic Therapy

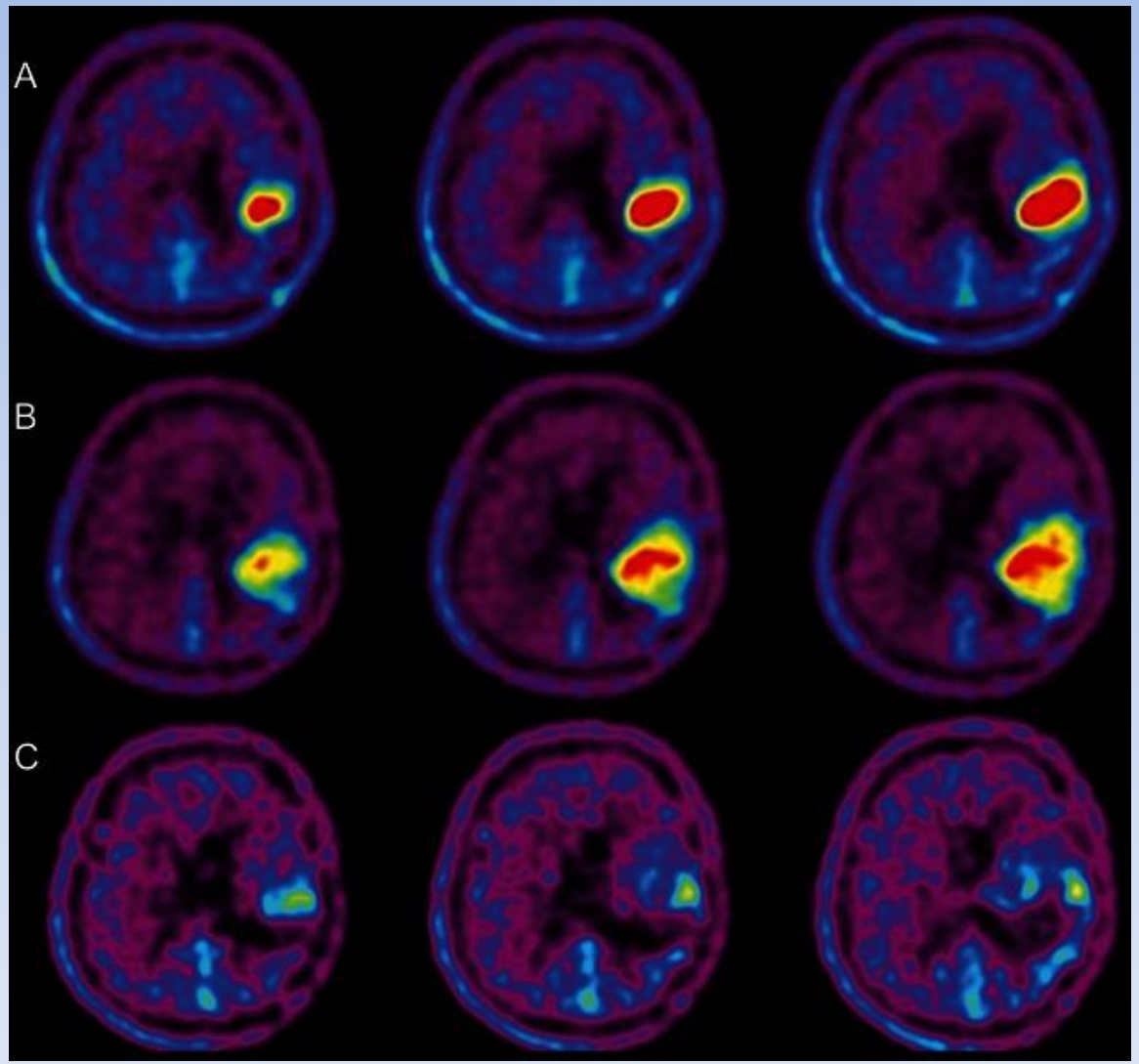

Fluorine-18-labeled boronophenylalanine
o
18F-Thyrosine

Differentiation of glioblastomas from metastatic brain tumors by tryptophan uptake and kinetic analysis: a positron emission tomographic study with magnetic resonance imaging comparison

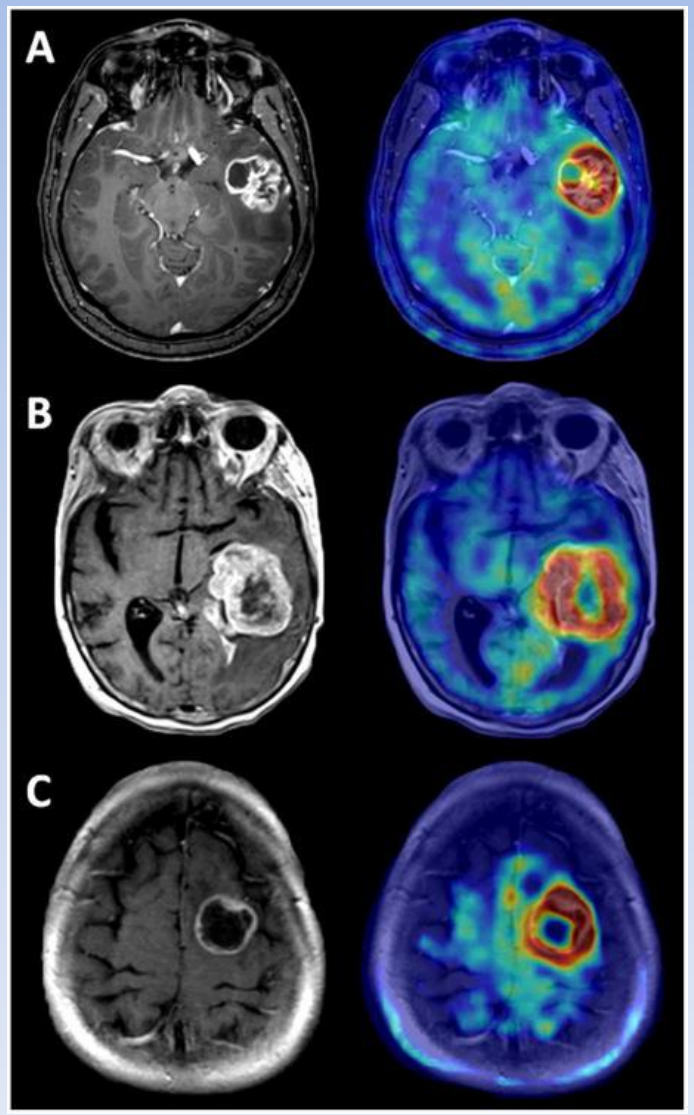

11C-triptofano nella differenziazione tra primitività e secondarismo.

Barriera Emato Encefalica

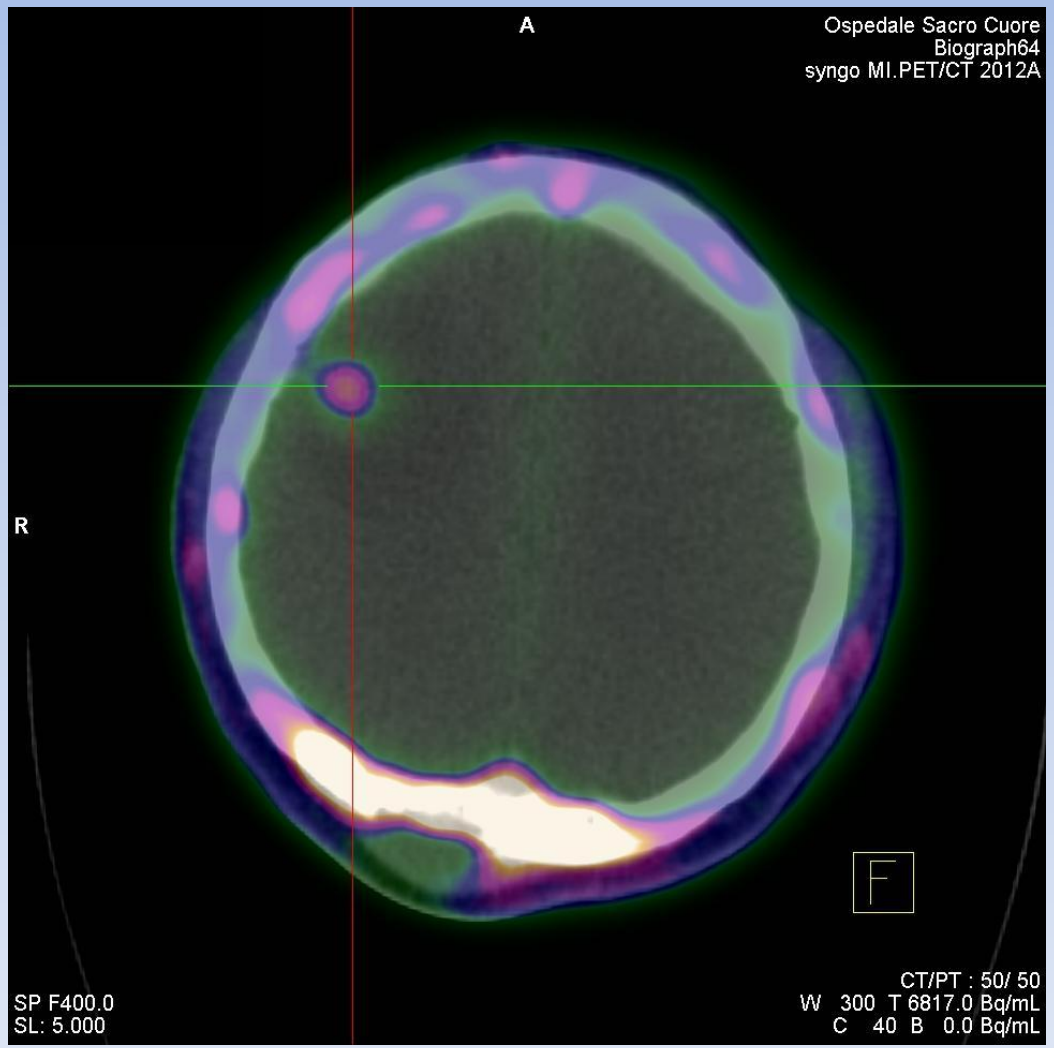

PET-TC con 18F-Na tracciante per osso che normalmente non supera la barriera.
Può rappresentare la misura dell'alterazione della BEE

Conclusioni

- PET-TC con FDG non risulta indicata nella stadiazione e ristadiazione cerebrale di eteroplasia mammaria

- Tracers specifici per target terapeutico e target istologico risultano in alcuni casi adeguarti (11C-Metionina) in altri casi fortemente promettenti (89Zr-Trastuzumab, 64-Cu-Dota-Trastuzumab)